

## THE ROLE OF PLATELET- RICH PLASMA IN LONG BONE DELAYED UNION: A PROSPECTIVE STUDY

Harshit Jain<sup>1</sup>, Umang Agrawal<sup>2</sup>, Shivam Dixit<sup>3</sup>

<sup>1</sup>Associate Professor in Krishna Mohan Medical College Mathura, Uttar Pradesh, India.

<sup>2</sup>Post Graduate Student in Krishna Mohan Medical College Mathura, Uttar Pradesh, India.

<sup>3</sup>Senior Resident in Krishna Mohan Medical College Mathura, Uttar Pradesh, India.

Received : 22/10/2023  
Received in revised form : 20/11/2023  
Accepted : 01/12/2023

**Keywords:**

Platelet-rich plasma, delayed union, and long bones.

Corresponding Author:

**Dr. Harshit Jain**

Email: hhh.miracle@gmail.com

DOI: 10.47009/jamp.2023.5.6.134

Source of Support: Nil,

Conflict of Interest: None declared

*Int J Acad Med Pharm*

2023; 5 (6); 650-653



### Abstract

**Background:** The purpose of this study was to evaluate the functional effect of platelet rich plasma (PRP) infiltration in delayed long bone union. **Material and Methods:** After obtaining written and informed consent, 25 clinically proven delayed union of long bones fracture patients were included in the study and treated with autologous PRP infiltration three times three weeks apart, with clinical and radiological evaluations. **Results:** Union was achieved in 22 of 25 patients (88%) at the end of six months, with three cases progressing to non-union. **Conclusion:** Platelet-rich plasma injected locally is beneficial in the treatment of long bone fractures with delayed union.

## INTRODUCTION

Delayed union occurs when an acceptable period of time has transpired since the initial injury without satisfactory bone union. In this condition, the fracture takes longer than usual to heal but shows progress towards healing over time. Long bone fracture healing times are as follows: Humerus (6-8 weeks), Femur Shaft (12 weeks), and Tibia (10 weeks). Delayed union occurs when the bone takes longer to heal than the prescribed time.<sup>[1,4,8]</sup>

There are several factors that might cause delayed union. It include both patient-related and fracture-fixation-related causes. Patient-related factors include old age, systemic sickness, osteoporosis, smoking, alcohol, and so on. Distraction at the fracture site, misalignment of fracture pieces, diminished viability of fracture fragments and poor immobilization are all issues connected to improper fracture fixation.<sup>[2,3,5]</sup>

Fracture healing is a complex physiological process that involves the coordinated interaction of hematopoietic and immunological cells inside the bone marrow, as well as vascular and skeletal cell precursors. Biological stabilization must be precisely balanced during the healing process. In some cases, this process may not progress as planned, and healing does not occur in the absence of appropriate assistance leading to delayed union. Hence, the biological and mechanical aspects should be considered first in the treatment of delayed union.<sup>[6,7]</sup> After obtaining mechanical stability, an attempt is made to achieve physiological union. This can be done either using bone graft or direct PRP infiltration. Bone grafting is a widely used therapy for delayed union. It functions as a scaffold, providing biomechanical strength and so promoting bone repair

but this is quite invasive procedure.<sup>[9]</sup> PRP provides high concentration of platelet-derived Growth Factor, Transforming Growth Factor Beta, vascular endothelial growth factor, Insulin-like Growth Factor-1, hepatocyte growth factor, and Fibroblast Growth Factor which is an autologous blood product.<sup>[16]</sup> These elements encourage the production of repair and granulation tissue. Substances secreted by active platelets influence and activate the intracellular signaling system for healing. PRP administered to the fracture site hence accelerate the physiological healing process, supports cell communication, lowers pain, and has anti-inflammatory and anti-bacterial properties leading to union.<sup>[10]</sup>

Several investigations have found that PRP has a positive effect on osteogenic proliferation.<sup>[11,12,13,14,15]</sup> We are evaluating the functional outcome of PRP in delayed union in our study.

## MATERIAL AND METHODS

From September 2021 to October 2023, 25 patients with Delayed Union of Long Bones were studied at Krishna Mohan Medical College Mathura's Department of Orthopaedics. The study comprised patients of either gender aged 18-65 years. The study included individuals who exhibited clinical and radiological evidence of delayed union 5 months after the original surgery. The study excluded patients with pathological fractures and documented non-union. The study design was addressed with each selected patient, and signed agreement was obtained prior to the study's start. Standard AP and lateral views were used to evaluate the patients. Patients are assessed using WU coring and m-RUST scoring system.

### Prp Prepration

In an ACD Gel PRP tube, 18ml of autologous blood is obtained from the patient. For 15 mints, the platelets are separated by centrifugation at 3400rpm. This separates whole blood into packed cells (sediment) which mixed into the gel, plasma, and platelet concentrate (supernatant) which was roughly 5 ml the above 3 ml was discarded and the remainder was shake so to obtain leucocyte rich PRP which is liquid is taken into a syringe of 10ml. The platelet concentrate should be used within 6 hours of being collected.

### Method of Infiltration

All infiltrations are performed in the operating room under local anesthesia in strict aseptic conditions under the supervision of C-ARM. A 10cc syringe is filled with platelet concentrate. Infiltration is performed with 18G stainless steel needles. Under C-arm guidance, a needle is introduced into the delayed union site (Fig. 1), and numerous pricks cause micro trauma at the site. The platelet concentration is injected into the region of delayed union.<sup>[17]</sup> We follow the patient at 21, 42, 63 and 6 months and taken mRUST score and WU score.

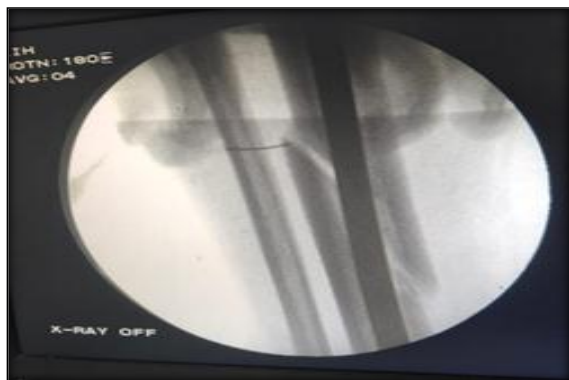
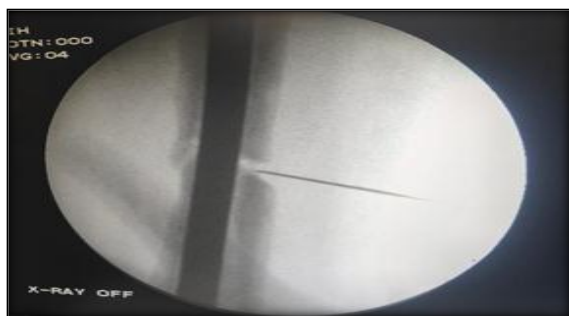
Figure 1: Infiltration of PRP

## RESULTS

In our study, the average age is 37 years. 88% Male and 12% Female Sex Incidence. Involved Bones is 52% Femur, 36% Tibia and 12% Humerus. Mean time from trauma to first PRP is 11.8 weeks. % of infiltration is 100% 3 times. The average amount of infiltration is 6.7 ML PRP. The average time between the first and second infiltrations was 21.8 days. The average time between the second and third infiltrations was 21.9 days. 4.4 Months = Mean Union Time All patients were not mobilized until the sign of union, and

no dynamisation was performed. The average time between PRP preparation and infiltration was 43.4 minutes.

OUTCOME (Figure 2)

- 80% = Excellent
- Good = 8%
- 12% are non-union.

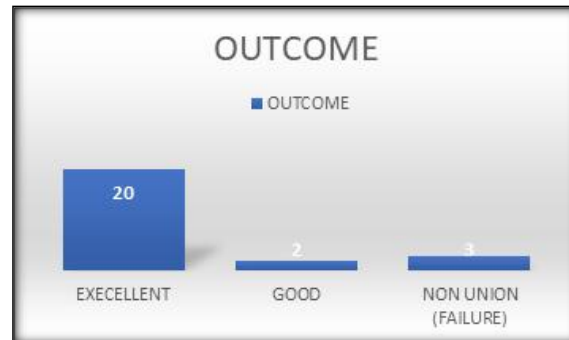
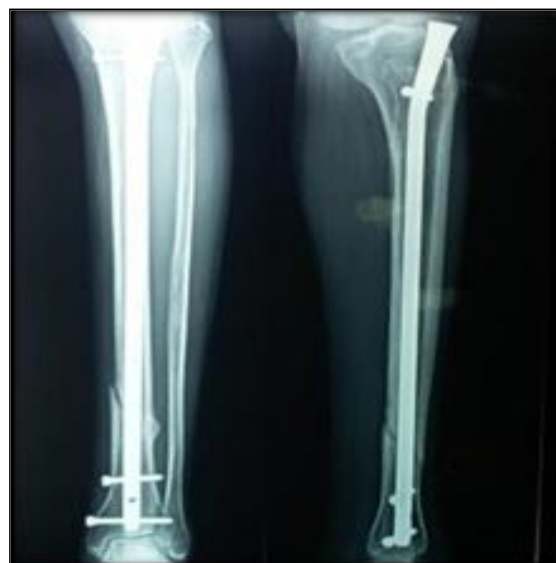
Figure 2:

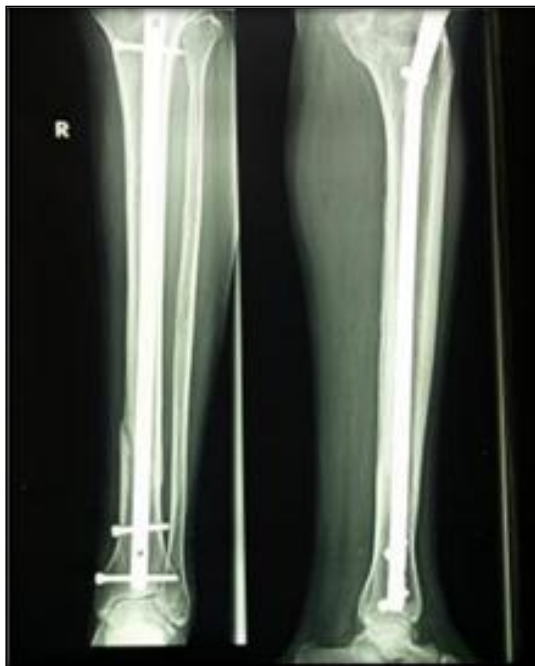In our study, we discovered that 22 patients out of 25 who underwent PRP infiltration three times, three weeks apart, and were followed up with X-Rays after six months had outstanding union results according to the Modified RUST Score of 84%, which is consistent with other studies.

In our investigation, three individuals had non-union surgery out of which one was chronic smoker, one was having uncontrolled diabetes and for one cause can be identified.

### CASE 1 (Figure 3)

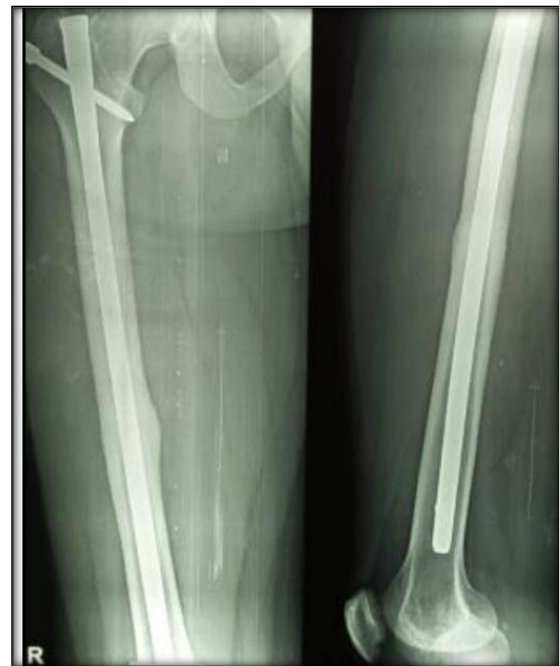

X-ray for Pre-Infiltration

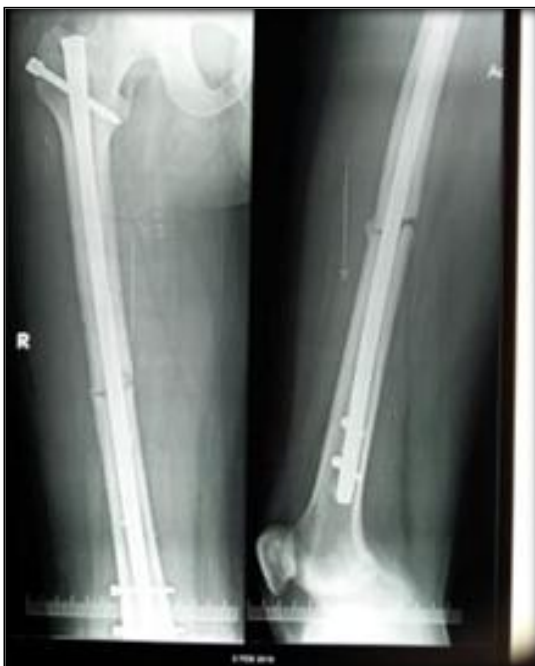

X-ray after infiltration

CASE 2 (Figure 4)



X-ray after infiltration



X-ray for Pre-Infiltration

## DISCUSSION

Delayed union of long bone has been a cribbing problem for orthopaedics surgeon. Treatment modalities ranging from bone graft to PRP are being used. In our study we make an endeavor to study the role of Platelet rich plasma in accelerating union in delayed union of long bones. PRP provides number of growth factors which acts in various ways (as shown in image below Figure 5) to promote bone healing. It is highly acclaimed method now days which is not only easy to administer but do not have any reaction due to autologous origin.

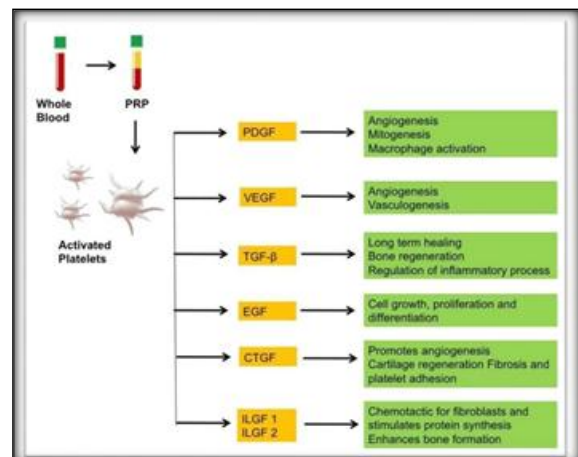


Figure 5:

In our study, we employed Modified RUS Scoring and WU scoring which is based on the visibility of the fracture line and the presence or absence of callus on plain radiographs six months after first PRP infiltration.

In our study, the age distribution that showed the most delayed union was 35-44yrs (35%) and the least was 45-54yrs (50%) and 55-64yrs (15%), which was in close correlation with the studies of Justynagolos et al. (41 years) and Deepak chaudhary et al. (32 years). In our study, the mean union time was 4.4 months, and the efficacy of PRP infiltration after a six month follow up was 84% union, which is consistent with the studies of Justynagolos et al, Deepak Chaudhary et al, where mean union time was about 4.05 months, 4.8 months, and union was seen in 81.8%, 83.3% cases, respectively.

In our study he have taken average of 6.7 ML of infiltrate, 3times three weeks apart and the time between preparation and infiltration of PRP was 43.4 min. There is no any approved literature for these parameters. Hence more studies are needed in the regard so more studies are needed in this regard.

**Table 1: Union Rate**

	Mean union time	The efficacy of PRP infiltration
Our study	4.4 months	84% union
Justynagolos et al. [18]	4.05 months	81.8% union
Deepak chaudhary et al. [19]	4.8 months	83.3% union

## CONCLUSION

Platelet-rich plasma growth factors injected locally are useful in the treatment of lengthy bone fractures with delayed union. But more studies are required to prove its efficacy in delayed union as there are certain limits for PRP that is less window period and no standard protocol.

## REFERENCES

1. Rüedi TP, Buckley RE, Moran CG. AO Principles of Fracture Management, 2007. ISBN: 3131174420.
2. Thelen M, Ritter G, Bücheler E. Radiologische Diagnostik der Verletzungen von Knochen und Gelenken., Ein Leitfadentext

3. Radiologen und Traumatologen. Thieme, 1993. ISBN: 3137787017.
3. McRae R, Esser M. Practical Fracture Treatment. Churchill Livingstone, 2008. ISBN:1455725234
4. Islam O, Soboleski D, Symons S et al. Development and duration of radiographic signs of bone healing in children. AJR Am J Roentgenol. 2000; 175(1):75-8
5. Tsiridis E, Upadhyay N, Giannoudis P. Molecular aspects of fracture healing: which are the important molecules? Injury. 2007; 38:11-25.
6. Solheim E. Growth factors in bone. Int. Orthop. 1998; 22:410-416.
7. Phieffer LS, Goulet JA. Delayed unions of the tibia. J Bone Jt Surg. 2006; 88-A:206-216.
8. Lavelle DG. Delayed union and nonunion of fractures. In Canale ST. editor. Campbell's operative orthopaedics. 10th ed. St. Louis, Mosby. 2003, 3126-3127.
9. Sen MK, Miclaur T. Autologous iliac crest bone graft: should it still be the gold standard for treating nonunions? Injury. 2007; 38:75-80.
10. Sánchez M, Anitua E, Orive G, Mujika I, Andia I. Platelet-rich therapies in the treatment of orthopaedic sport injuries. Sports Med. 2009; 39:345-354.
11. Bielecki T, Gazdzik TS, Szczepanski T. Benefit of percutaneous injection of autologous platelet-leukocyte rich gel in patients with delayed union and nonunion. Eur. Surg. Res. 2008; 40:289-296.
12. Calori GM, Tagliabue L, Gala L, D'imperzano M, Peretti G, Alibisetti W. Application of rhBMP-7 and platelet-rich plasma in the treatment of long bone non-unions: a prospective randomised clinical study on 120 patients. Injury. 2008; 39:1391-1402.
13. Sanchez M, Anitua E, Cugat R, Azofra J, Guadilla J, Seijas R et al. Nonunions treated with autologous preparation rich in growth factors. J Orthop. Trauma. 2009; 23:52-59.
14. Seijas R, Santana-Suarez RY, Garcia-Balletbo M, Cuscó X, Ares O, Cugat R. Delayed union of the clavicle treated with plasma rich in growth factors. Acta. Orthop. Belg. 2010; 76:689-693.
15. Aslani H, Nourbakhsh ST, Zafarani Z et al. Platelet-Rich Plasma for Frozen Shoulder: A Case Report. Arch Bone Jt Surg. 2016; 4(1):90-93.
16. Choi HM, Kim HM, Kim CK et al. The Cheapest and Easiest Way to Make Platelet-rich Plasma Preparation. Arch Aesthetic Plast Surg. 2015; 21(1):12-17.
17. Sridhara Murthy JN, Bharath Raju G, Manoj Kumar. Autologous platelet concentrates infiltration in management of Delayed/Non-Union of fractures Technical Note and Tips- Journal of orthopaedics and Rehabilitation, 2011, 1(1).
18. Justyna Gołos ABCDEF, Tomasz Waliński ABCDEF, Piotr Piekarczyk CD, Krzysztof Kwiatkowski ADF. Results of the Use of Platelet Rich Plasma in the Treatment of Delayed Union of Long Bones. 2014; 4(6):397-406.
19. Deepak Chaudhary, Kumar Rohit, Rajeswar Kalla. Functional outcome and results of platelet rich plasma (PRP) in treatment of delayed union, 2016, 5(1). ISSN No. 2277-8179.